

# *Dermatoses in the AIDS*

L. Olmos Acebes and M.A. González Intxaurreaga

---

## SUMMARY

The authors report shortly on their experience in diagnosing and treating skin manifestations in the early and late stages of HIV infection. They believe that by careful observation of skin symptoms it is possible to suspect with great probability the HIV infection. According to their experience they range the symptoms into three major groups. The most frequent disorders: seborrheic dermatitis, candidiasis, condyloma acuminatum, herpes simplex, Kaposi's sarcoma, and dermatophytosis.

Dermatoses with aggressive course: syphilis, cutaneous leishmaniasis, necrotising folliculitis, necrotising gingivitis, herpes zoster, molluscum contagiosum, scabies and papular pruritic eruption. Exceptional dermatoses: psoriasis, oral hairy leukoplakia, and prurigo.

This review was prepared in order to help the dermatologists and general practitioners in screening the HIV positive patients.

---

## *Introduction*

About 90% of patients infected with the Human Immunodeficiency Virus (HIV) present some manifestation on the skin and mucous membranes (1,2), which can be not strictly assigned to the different stages of this infection: the asymptomatic HIV positive patients, those affected by the AIDS Related Complex (RCA), and patients with expressed AIDS. Contrary to the symptoms in the early stages of HIV infection, the manifestations in fully expressed AIDS are less characteristic compared to the symptoms observed in routine dermatological cases.

Skin disorders in these patients may appear atypical, they may be widespread, have a more prolonged course, and the response to treatment may be poorer than expected.

Some years ago the World Health Organization (WHO) recommended including the HIV infection into Sexually Transmitted Diseases (STD). The Human Immunodeficiency Virus presents the same multidisciplinary, epidemiological, preventive, and social problems, which fact justifies WHO decision.

**K E Y  
W O R D S**

**dermatoses,  
HIV infected  
persons,  
AIDS**

## Clinical observations

### Most frequent dermatoses

#### Seborrheic dermatitis (SD)

Seborrheic dermatitis (SD) is without doubt the most common dermatosis in HIV-infected patients and is often the only sign of infection occurring in up to 50% of cases (2).

Clinically SD is characterized by a mild to severe erythema with irregular shape, whitish or yellowish scales and a greasy appearance, involving the seborrheic skin regions: the scalp, temples, retroauricular folds, outer parts of the ears, eyebrows, eyelids, glabella, nasolabial folds, and the midline areas of the chest and back. Less frequently intertriginous spaces are involved and widespread lesions may occur. The course is usually chronic.

The histopathologic findings are similar to those seen in non HIV-infected individuals.

Although SD is always associated with a constitutional seborrheic state and the clinical findings worsen as the disease progresses, and clear as the immune situation improves, this is due to infection to *Pityrosporum ovale* or *Pityrosporum orbiculare* (3).

The treatment is essentially local with shampoos containing imidazoles, corticosteroid creams and hygienic measures.

#### Oropharyngeal candidiasis (OC)

*Candida albicans* is a facultative pathogenic saprophyte and in 60% of normal individuals colonizes the oropharyngeal tract, but in HIV-seropositive patients this may be a valuable marker indicating a compromise of defense mechanisms of the mucosa.

Oral candidosis is the most common infection in HIV-infected patients. It is evident that this infection can also be located on other mucosal surfaces like the gland, the coronary sulcus of penis, the vagina or anus, and even in the cutaneous folds and nails, but the relation with AIDS is more difficult to interpret (4, 5). Disseminated candidiasis in severely immunocompromised HIV-infected patients has rarely been reported, but it is usually fatal.

Clinically there are small white lumps which, when removed, leave an underlying erythematous base located on the buccal epithelium of the cheeks, gums, palate or of tongue. In severe cases, extension to the pharynx or to the oesophagus may occur and erosive complications commonly cause severe symptoms resulting in inadequate food intake.

The treatments are always deceiving due to the frequent relapses despite the good immediate effects.

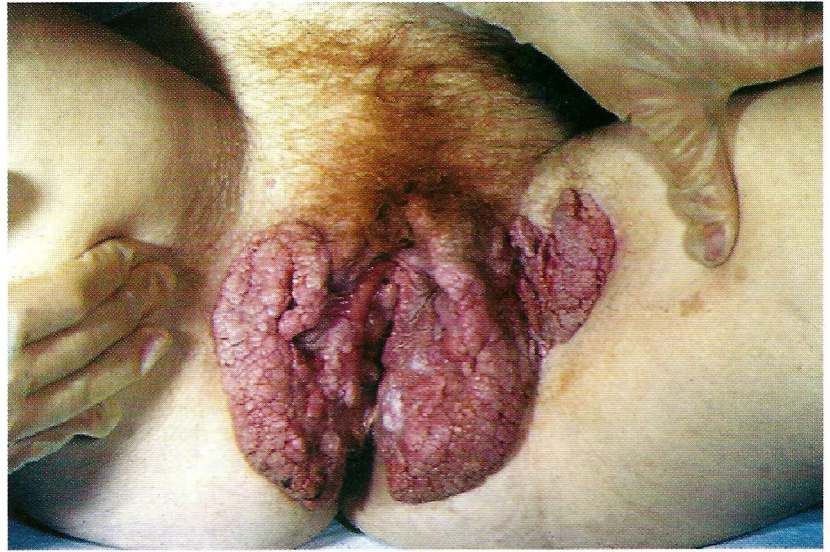


Fig. 1 Condyloma acuminatum giganteum.

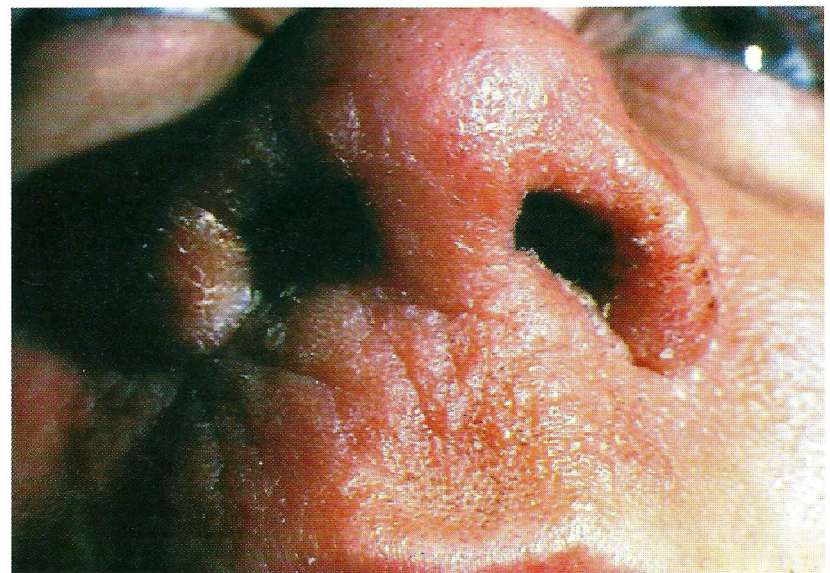Therefore a simultaneous local and oral treatment with flutrimazol, itraconazol, piroxolamin or fluconazol has to be used.

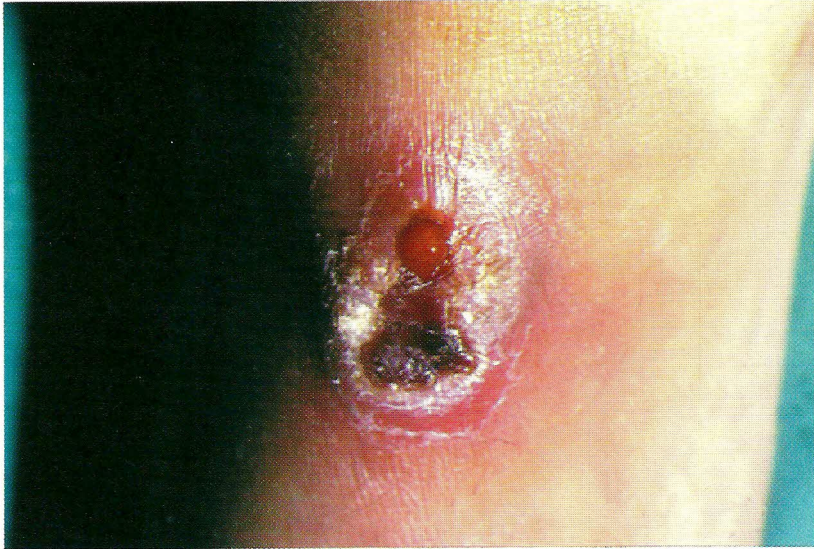#### Condyloma accuminatum (CA)

After SD and OC condyloma accuminatum is the third most common cutaneous affection in HIV-infected patients, detected in more than 30% of the seropositive individuals (6).

The clinical patterns that can be seen comprehend all the spectra known. In the early HIV disease, the clinical manifestations, clinical course and response to treatment are not unusual. With moderate or advanced immunodeficiency, the HPV lesions may become con-

Fig.2. Cutaneous leishmaniasis nasal aria.



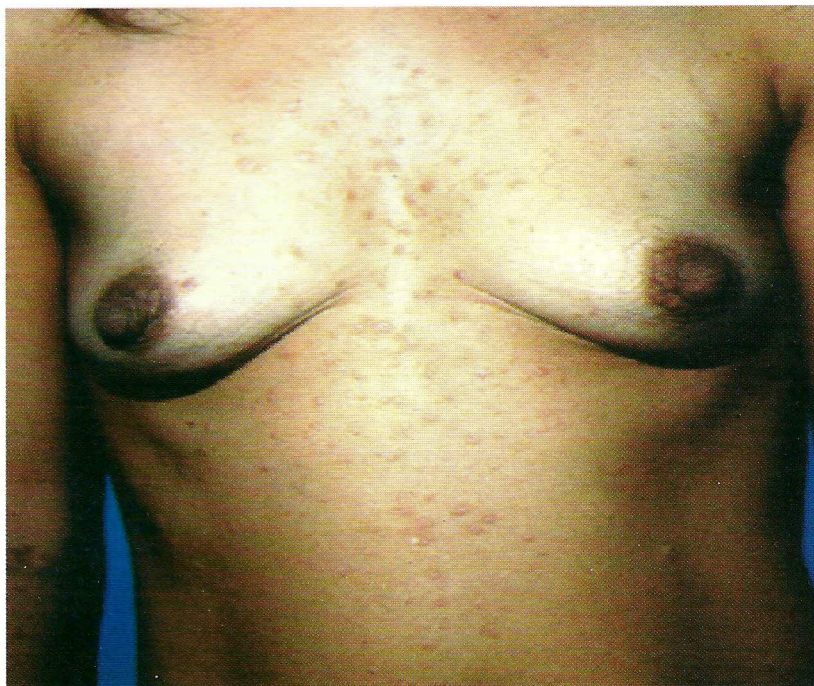

**Fig. 3. Necrotizing folliculitis.**

fluent, much more numerous, unresponsive to usual treatment, and may appear in unusual places (Fig. 1).

Unfortunately, no therapy has been devised to eradicate HPV entirely; thus it is necessary to use a combined local treatment. A variety of antimetabolic agents are widely employed like podophyllin resin, purified podophyllotoxin or 5-fluorouracil. Surgery, cryotherapy, electrocoagulation, lasertherapy, and intralesional

**Fig.4. Papular pruritic eruption.**



interferon-alpha are also standard measures used for HPV infection (7). Recently new topics, such as imiquimod or 3% cidofovir ointment, have been successfully used.

### *Herpes simplex (HSV)*

In patients with AIDS the herpes simplex virus, type 2 infection has a prevalence of nearly 20% (4, 8).

The clinical signs of the genital herpes rarely allow to suspect the immunodeficiency, though in cases of a significant immunosuppression the lesions may run a prolonged and atypical course with more destructive nerve lesions or a very chronic course, even with an appropriate therapy.

Among the most remarkable complications, besides *erythema multiforme*, the disseminated or systemic infection has to be mentioned. It appears, however, with severe immunodeficiency.

The treatment of choice for the HSV infection is Valaciclovir, an aciclovir prodrug, with a better oral availability. The use of a topical antiseptic may help to reduce the risk of secondary bacterial infection. In severe HSV infection, possibly resistant to aciclovir, systemic phosphonoformate (Foscarnet) may be considered.

### *Kaposi's sarcoma (KS)*

KS is a vascular neoplastic disorder and it is observed much more frequently in homosexuals than in intravenous drug users. KS is caused by the infectious agent HHV-8 (Human Herpes virus Type 8) that has been shown to be transmitted sexually (9).

The prevalence in Spain does not exceed 6% of the HIV-infected persons, contrary to what it happens in most countries worldwide where 11% of seropositives can be observed (10), though this prevalence has dropped significantly (11).

The treatment of this neoplasm has been based on Interferon alpha. However, at present the combined treatment with two virostatics and a protease inhibitor (HAART) is recommended.

### *Dermatophytosis*

Up to 20% of HIV-infected persons have dermatophyte infections. This prevalence is similar to that seen in HIV non-infected individuals.

### *Aggressive dermatoses*

Practically all the dermatological pathology can be observed during the evolutionary stages of AIDS.

### *Syphilis (S)*

Syphilis is quite frequent in patients with HIV infection, with a prevalence of 18-30%.

The symptoms of this oldest and best-known sexually transmitted disease in AIDS patients are less characteristic and thus more difficult to diagnose. Atypical clinical and serological findings are frequent. Examples include rapid progression from the primary chancre to the later stages of *S. maligna* and widespread gummata. The central nervous system manifestations are more frequent and more severe (12, 13).

The *Treponema pallidum* has never shown resistance to penicillin and continues to be the treatment of choice.

### *Cutaneous leishmaniasis (CL)*

The main area of overlap is Southern Europe, especially Spain.

The clinical manifestations, though really aggressive, are not displaying necrosis. The lesions are situated in exposed areas, but the inoculation point is sometimes undetectable. The granulomatous lesions are usually spreading (Fig. 2).

Making a smear of material from the sore and staining it with Giemsa on a microscope slide can confirm the infection by demonstration of the parasite while histopathology confirms histiocytes full of *Leishmania* with lymphocytic reaction that possibly facilitates the extension of injuries and even of the scattering (14).

The treatment with pentavalent antimonials is efficient.

### *Necrotizing folliculitis (NF)*

All the pyogenic bacterial infections are commonly encountered in HIV patients with a prevalence of 3-11% of cases. Much more rare is the NF that is manifested as suppurative or abscess-like lesions with serohematic and blackish scabs developing in 2-3 days from isolated pustules. The lesions may be scattered anywhere on the skin (Fig. 3). Generally, there is not a defined bacteriology, and the healing is slow and unaesthetic (15).

NF is treated with the application of topical antiseptics with good results, but in general it resolves with unaesthetic scars.

### *Necrotizing gingivitis (NG)*

A mixed flora like the fusospyrochetæ complex, candida, gram-positive cocci, herpes virus, cytomegalovirus, and other organisms may cause acute necrotizing gingivitis in immunocompromised host.

The clinical manifestations, including gingival soreness, bleeding and halitosis may develop into necrosis

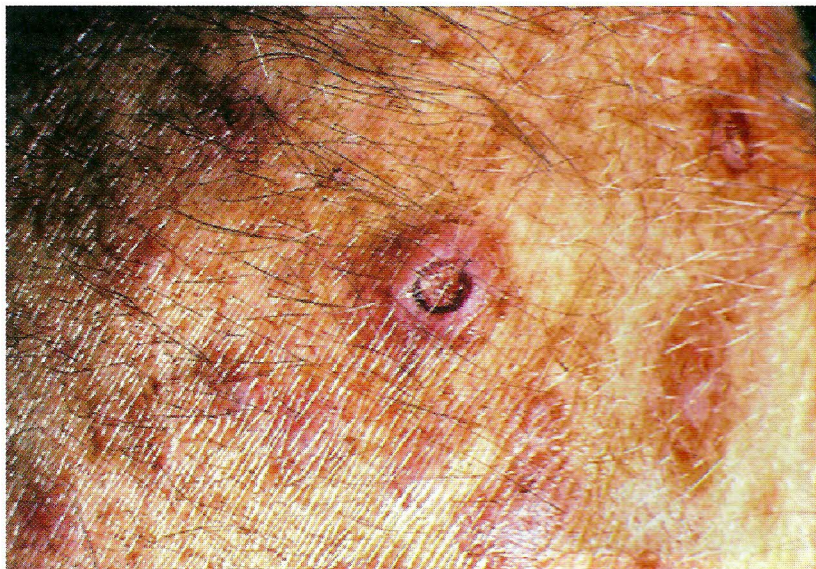
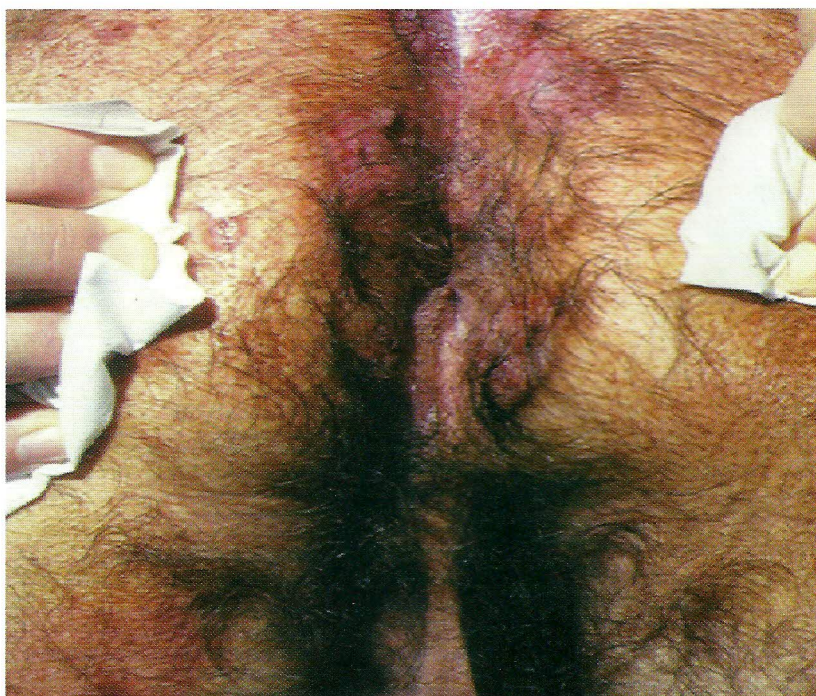

Fig. 5. Prurigo, a detail.

and destructions with loss of teeth and further functional problems. There is often enlargement of the cervical lymph nodes with pyrexia and malaise.

The treatment is complicated because to the topical antiseptics we have to add antivirals like valaciclovir, metronidazole or penicillin depending on the gravity and the etiology.

Fig. 6. Perianal prurigo.



### *Herpes zoster (HZ)*

According to the few publications, the prevalence oscillates between 6 and 9% of HIV-infected persons.

HZ in HIV-infected patients is more serious than similar infections in immunocompetent hosts, because painful atrophic scars, persistent ulcerations, multi-dermatomal involvement, recurrent zoster infections, and secondary episodes of varicella may be seen. Severe pain and persistent postherpetic neuralgia may also develop.

The treatment is with one of the thymidine kinase inhibitors, such as acyclovir, valacyclovir, and famcyclovir (4, 8). Resistant cases require treatment with intravenous application of foscarnet.

### *Molluscum contagiosum (MC)*

MC is usually a benign viral infection. However, in immunocompromised patients it may become widespread, disfiguring and unresponsive to treatments.

Sometimes other cutaneous disorders (cryptococcosis, pyogenic granuloma, keratoacanthoma, basal cell carcinoma) can mimic Molluscum contagiosum infection, consequently a biopsy is often necessary.

MC infection is often accompanied by other viral infections, especially by papillomavirus.

The usual method of treatment is curettage, but due to the bleeding that can be produced, the cryotherapy and, recently, the cydofovir are advisable.

### *Scabies*

Scabies may be sexually transmitted and it is one of the most frequent skin disorders to develop in HIV-infected patients.

Scabies may have a number of different clinical manifestations in seropositive individuals, ranging from classic features to crusted (Norwegian) scabies in which a great number of mites are present and the itching is reduced.

Scabies in HIV-infected patients may mimic psoriasis, atopic dermatitis, seborrheic dermatitis, lymphomatoid papulosis, and insect bite reactions. The diagnosis is confirmed by examination of scrapings, which demonstrates mites and eggs.

Treatment is usually similar to that used in immunocompetent hosts, though several applications of a scabicide may be necessary. It is important that all partners should be treated simultaneously.

### *Papular pruritic eruption (PPE)*

More and more frequently the PPE, an extremely pruritic dermatosis characterized by red or skin-colored, non-confluent micro-papules on a xerotic skin, invol-

ving widespread areas, most commonly the trunk, extremities and folds, can be observed (Fig. 4).

Clinically and histologically, PPE is similar to eosinophilic papulosis of Ofuji, and in the early stages can easily be confused with scabies (16).

The classical therapies are systemic antihistamines, oral prednisone, and topical corticosteroid preparations, but the treatment that seems to be more effective is the exposure to ultraviolet B phototherapy.

### *Exceptional dermatoses*

The list in this group could be very long, but we will name only the lesions that may be more significant to suspect the HIV infection.

#### *Psoriasis (P)*

There are scores of descriptions ranging from the transitional whitening with the first symptoms of HIV infection to appearance of the first outbreak after the infection in an individual who has never before had a clinical disease. Nevertheless, nowadays the publications about complicated psoriasis are more frequent in view of the intensity, frequency and extension of the outbreaks, or due to the associated symptoms like arthritis, erythroderma or inverted psoriasis (17).

The therapy depends on the extension and the associated symptoms of the disease. The existing hematic and hepatic changes limit the systemic treatment. The use of psoralen and ultraviolet A therapy is also effective.

#### *Oral hairy leukoplakia (OHL)*

This clinical manifestation is detected in about 2.5-10% of cases, even though the incidence of this disorder is decreasing in HIV patients as a consequence of HAART (highly active anti-retroviral therapy) like other cutaneous manifestations of HIV infection.

Most commonly, OHL is manifested as corrugated, whitish and asymptomatic plaques situated along the lateral borders of the tongue, rarely bilaterally. With the electron microscopy papilloma virus and Epstein-Barr virus have been detected in the lesion.

The most practical treatment is the cryotherapy, though treatment is not always indicated.

#### *Prurigo*

The etiology of the process is not fully known. The clinical and histopathologic findings may resemble classic prurigo nodularis found in immunocompetent hosts (Fig. 5). Nevertheless, prurigo seems to be a reaction pattern that may be associated with some bacte-

rial or viral infections, especially in the anus area, secondary to HIV infection (18) (Fig. 6).

Treatment is mainly directed at suppressing the itching and avoiding secondary infections. Recently thalidomide has been shown to be effective.

## Conclusion

It is the authors' suggestion that a solid knowledge of dermatology combined with careful observation of symptoms and a thorough patient's history are important clues in detecting HIV positive persons.

## REFERENCES

1. Mathes BM, Douglas MC. Seborreic dermatitis in patients with the acquired immunodeficiency syndrome. *J Am Acad Dermatol* 1985; 13:947-951.
2. Muñoz Pérez MA. Manifestaciones cutaneomucosas en pacientes VIH positivos: incidencia, correlación clínica, inmunológica y dermatopatológica. Estudio prospectivo de 1161 pacientes. *Actas Dermosifiliogr* 1999; 90: 11-20.
3. Baradad M, Castel T, Irazzo P. Manifestaciones cutáneas del sida. *Piel* 1987;2:392-409.
4. Janier M, Reynaud B, Gerbaka J, Hakim C, Rabian C, Morel P. Signes cutanés de l'infection par le VIH: étude prospective de 267 patients. *Ann Dermatol Vénéréol* 1994; 121 (supl.1):46-47.
5. Valle SL. Dermatologic findings related to human immunodeficiency virus infection in highrisk individual. *J Am Acad Dermatol* 1987; 17: 951-961.
6. Palacios S, Maldonado R, Olmos L. Enfermedades de Transmisión Sexual y Virus de la Inmunodeficiencia Humana. *Rev.Ibero-Latinoamericana de E.T.S.* 1989;3:412.
7. Olmos L. Condilomas acuminados (Verrugas genitales) I y II. *Rev.Ibero-Latinoamericana de E.T.S* 1990; 4: 73-81 and 131-142.
8. Smith KJ, Skelton HG, Yeager J. Cutaneous findings in HIV-1-positive patients: a 42-month prospective study. *J Am Acad Dermatol* 1994; 31:746-754.
9. Moore PS, Chang I. Detection of herpesvirus-like DNA sequences in Kaposi's sarcoma in patients with and those without HIV infection. *N Engl J Med* 1995; 332:1181-1185.
10. Coldiron BM, Bergstresser PR. Prevalence and clinical spectrum of skin disease in patients infected with human immunodeficiency virus. *Arch Dermatol* 1989;125:357-361.
11. Haverkos HW, Friedman-Kien AE, Drotman DP et al. The changing incidence of Kaposi's sarcoma among patients with AIDS. *J Am Acad Dermatol* 1990; 22:1250-1253.
12. Olmos L. Sífilis. In: Farreras/Rozman: *Medicina Interna*. Barcelona. Ed. DOYMA, S.A. 1992: 2312-2318.
13. Olmos L. Infecciones por Treponema. In: Diaz-Rubio/Espinos: *Tratado de Medicina Interna*. Madrid. Ed. PANAMERICANA 1994:1754-1759.
14. Belmar JM, Santidrian V, Ortega V, Olmos L. Leishmaniasis cutánea centrofacial infiltrada en sábana. *Rev. Iberolatino-Amer ETS* 1994; 8:211-216.
15. Ferrandiz C, Ribera M, Barranco JC, Clotet B, Lorenzo JC. Eosinophilic folliculitis in patients with acquired immunodeficiency syndrome. *Int J Dermatol* 1992; 31:193-195.
16. Hevia O, Jiménez-Acosta F, Ceballos PI, Gould EW, Penneys NS. Pruritic papular eruption of the acquired immunodeficiency syndrome: a clinicopathologic study. *J Am Acad Dermatol* 1991; 24:231-235.
17. Obuch ML, Maurer TA, Becker B, Berger TG. Psoriasis and human immunodeficiency virus infection. *J Am Acad Dermatol* 1992; 27:667-673.
18. Raventos C, Borderas MA, González C, Olmos L. Infección simultánea por 6 tipos de virus diferentes más bacterias, hongos, dermatitis seborreica, dermatitis pruriginosa y Kaposi. *Rev. Iberolatino-Amer ETS* 1993; 7:177-179.

## AUTHORS' ADDRESSES

*Luis Olmos Acebes MD, Professor and Head of the STD service, Servicio de Dermatología, Hospital Universitario "San Carlos", Madrid, Spain*  
*Gonzalez Intxaurreaga Maria Angeles MD, Clinica Dermatologica, Ospedale di Cattinara, Strada di Fiume, 34149 Trieste, Italy*